



The use of MEDIHONEY® in Palliative Wound Care and the Advanced Aging Patient



Presenter: Angel Sutton, RN, MSN/Ed, CWCN, CFCN, CCCN
Wound Care Nurse Consultant

Agenda

- My clinical practice
- Why MEDIHONEY®? What can it do?
- A Review of Cases
- Impact on my practice
- Tips & Pointers
- Q&A

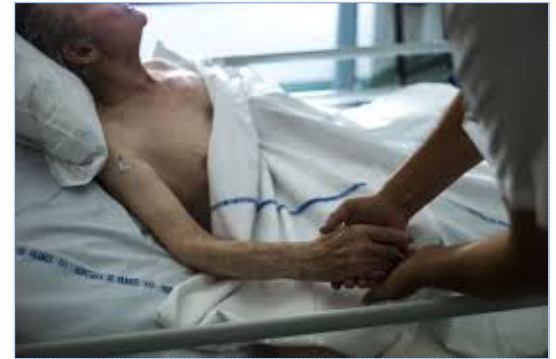My Clinical Focus: Long Term Care

- 55 Skilled Nursing Facilities
- 5 Home Health
- 5 Hospice
 - 30-50 Patient Consults/Wk
 - Wound Care Protocols/ Staff training



What is Palliative Wound Care?

- Hospice and Comfort Care
- Focus: relieve and prevent suffering
- All disease states
 - End of life
 - Curable diseases (ie. Cancer)
- Interdisciplinary team approach



Dr. Alvarez 2013

Description of Wound Care: S.P.E.C.I.A.L

S=Stabilizing the wound

P=Preventing new wounds

E=Eliminate odor

C=Control pain

I=Infection prophylaxis

A=Advanced, absorbent wound dressings

L=Lessen or reduce dressing changes

MEDIHONEY®®

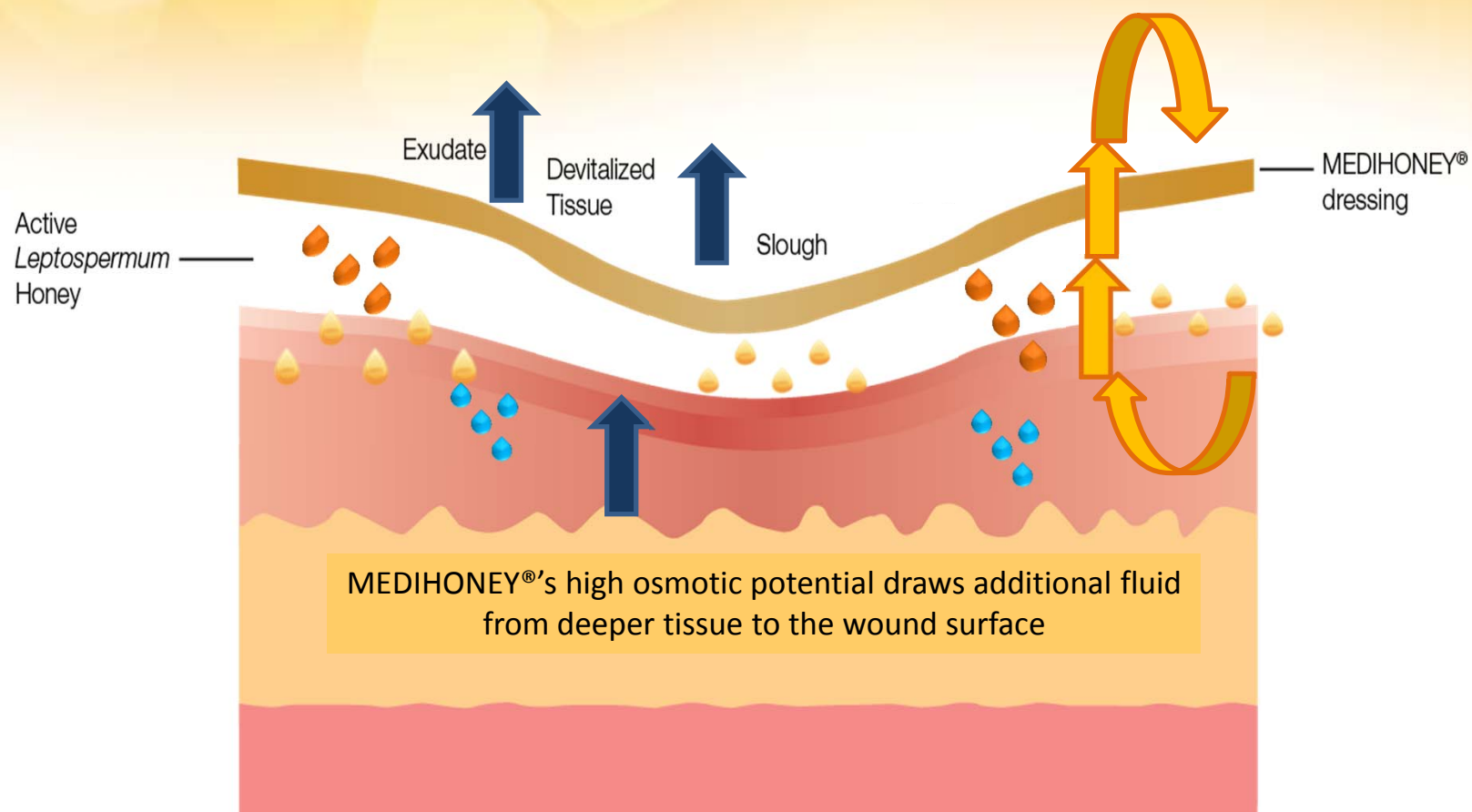
Promoting Autolytic Debridement through to Healing

- Derived from the pollen and nectar of a specific *Leptospermum* species of plant in New Zealand
- Unique among honey – maintains its effectiveness even in the presence of wound fluid
- Shown in randomized controlled trial where the mean healing time was significantly faster for wounds treated with MEDIHONEY® impregnated dressings when compared to conventional dressings¹
- Two key mechanisms of action create an optimal environment for wound healing – High Osmolarity and Low pH




1. Kamaratos AV, Tzirogiannis KN, Iraklianos SA, Panoutsopoulos GI, Kanellos IE, Melidonis AI. Manuka honey-impregnated dressings in the treatment of neuropathic diabetic foot ulcers. *Int Wound J.* 2012 ; 9: 1-7.

High Osmolarity



Works with the body's natural processes to promote autolytic debridement to cleanse debris and necrotic tissue from the wound

Low pH



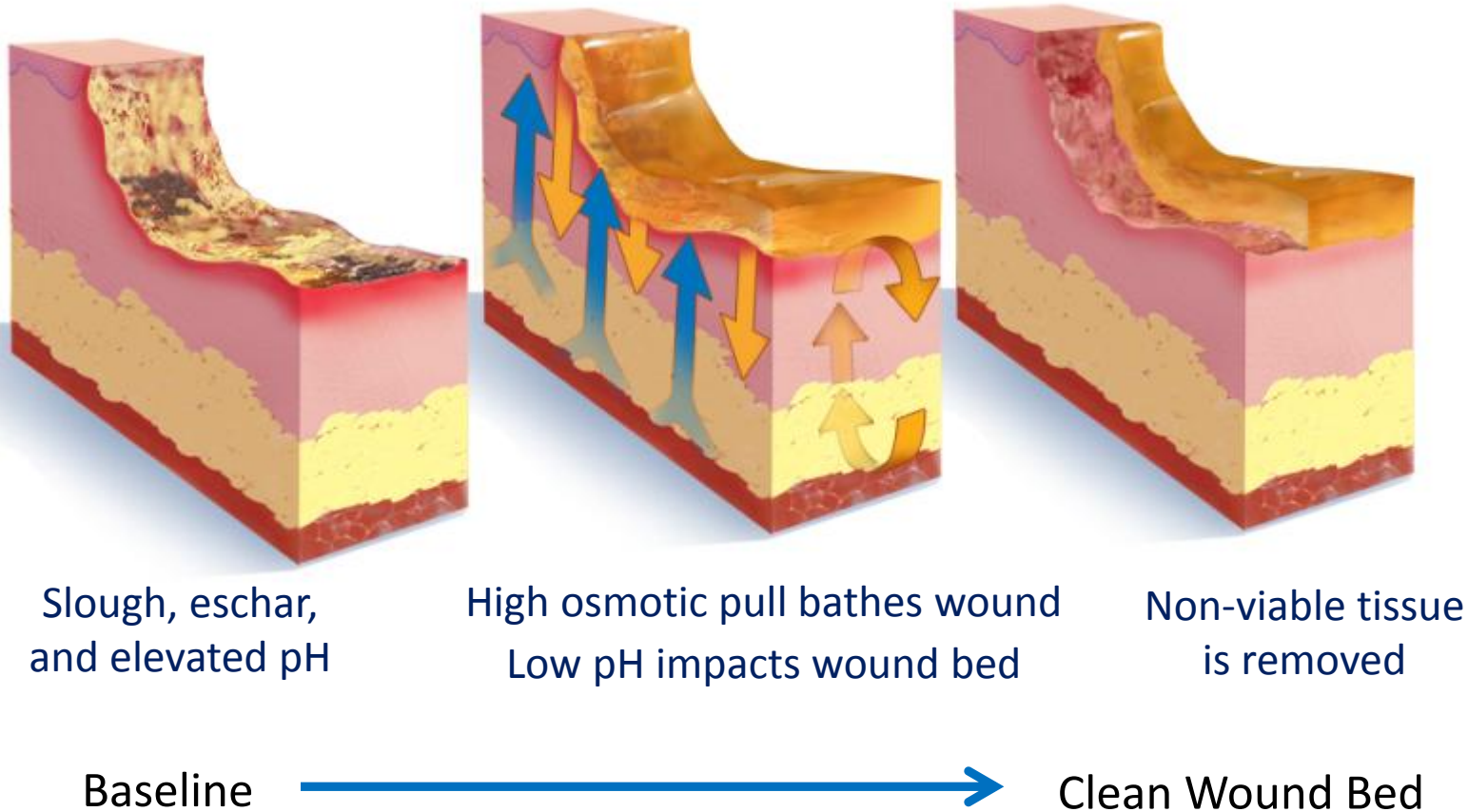
The low pH of MEDIHONEY® (3.2-4.5) helps to lower the pH within the wound environment^{2,3}, which has been shown to have wound healing benefits.⁴

2. Gethin G, Cowman S. Changes in pH of chronic wounds when honey dressing is used. In: Wounds UK Conference Proceedings; 13–15 November 2006. Wounds UK, Aberdeen.

3. Milne SD, Connolly P. The influence of different dressings on the pH of the wound environment. J Wound Care. 2014 Feb;23(2):53-4, 56-7.

4. Leveen H, Falk G, Borek B, Diaz C, Lynfield Y, Wynkoop B, Mabunda GA et al. Chemical acidification of wounds. An adjuvant to healing and the unfavourable action of alkalinity and ammonia. *Annals of Surgery*. 1973. 178(6): 745-50.

Two Mechanism of Action Promoting Autolytic Debridement

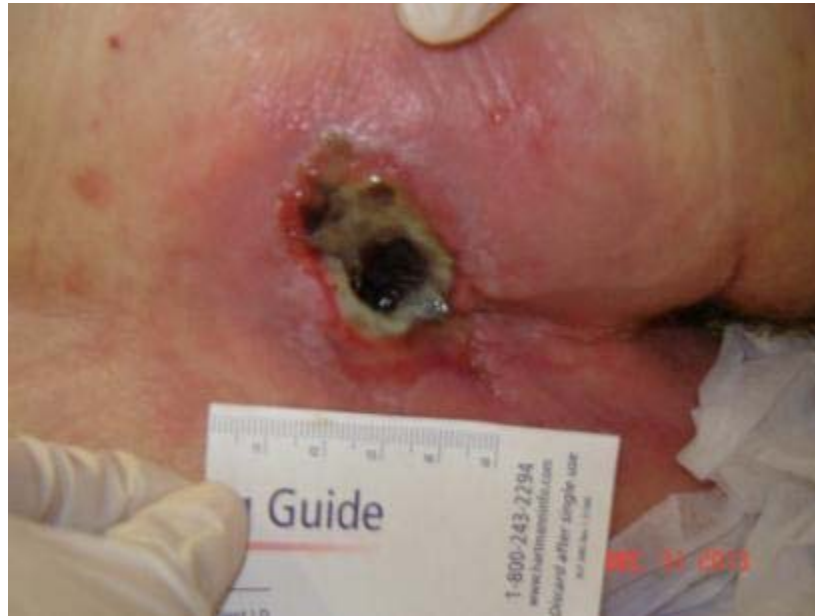

The background of the slide is a light yellow color with a bokeh effect. It features several out-of-focus, hexagonal shapes in various shades of yellow and orange, scattered across the top and bottom edges, creating a decorative border. The central area is plain white.

Case Review

Case 1 – Un-stageable Pressure Ulcer, Kennedy Terminal Ulcer

Day 1

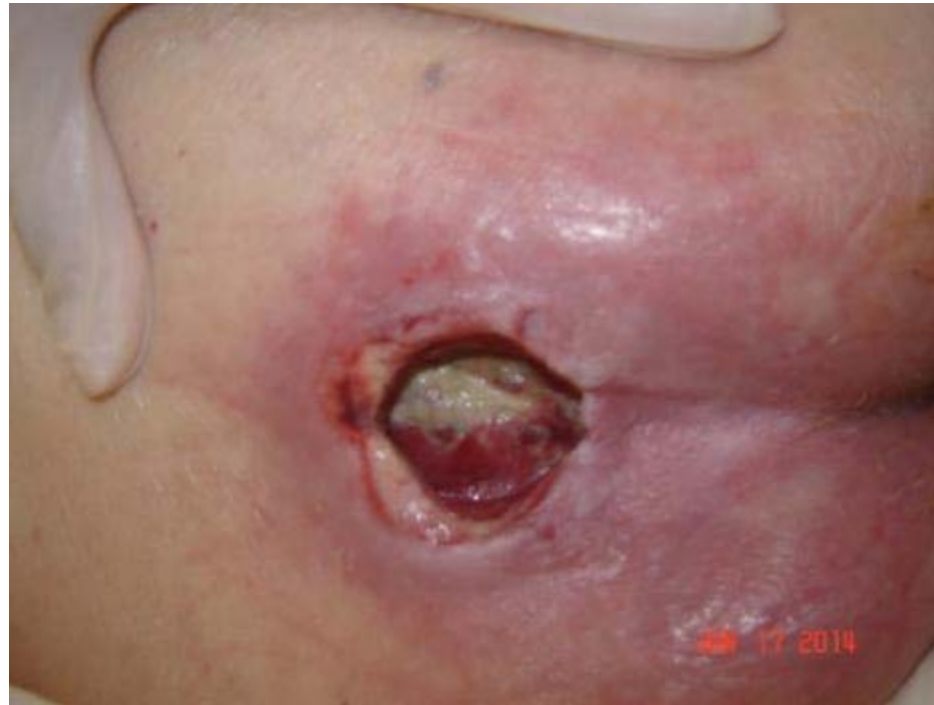

Wound
Measurements
3 x 2.8 x 1.5cm

- 93 year old male patient with respiratory failure with exacerbated CHF
- Patient was noted to have a coccyx un-stageable pressure ulcer with odor
- Applied MEDIHONEY® Calcium Alginate to wound bed to remove slough
- Covered with foam dressing
- Dressing changes 3x per week, versus everyday

Case 1 – Unstageable Pressure Ulcer

Day 18



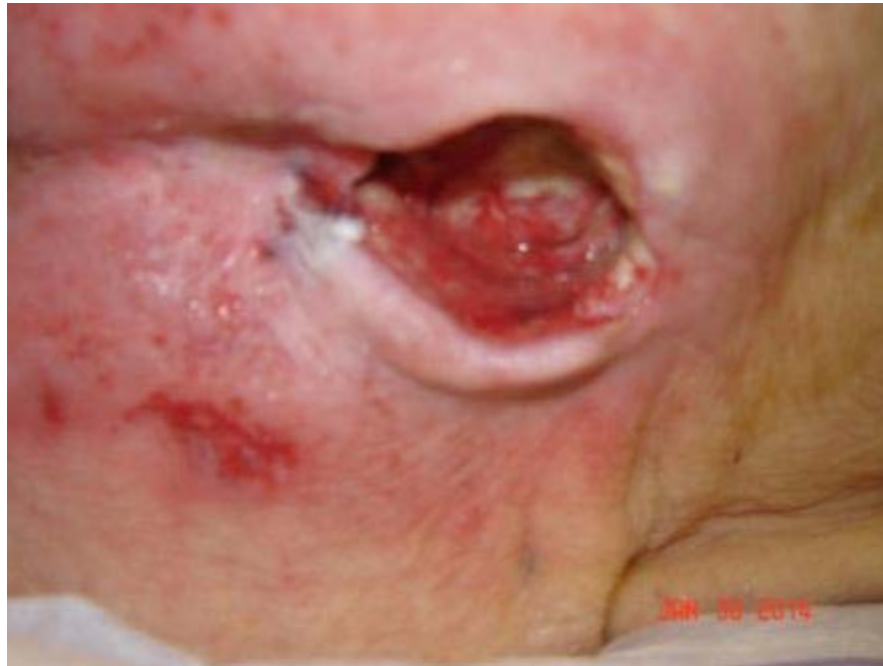Slight increase
in wound size

Measurements
3.5 x 3.2x 1.5

- Wound becoming clean of slough and non-viable tissue
- Patient observed a notable decrease in wound odor
- Continued with MEIDHONEY® calcium alginate and 3x week dressing changes to aid in wound healing and patient comfort

Case 1 – Unstageable Pressure Ulcer

Day 30

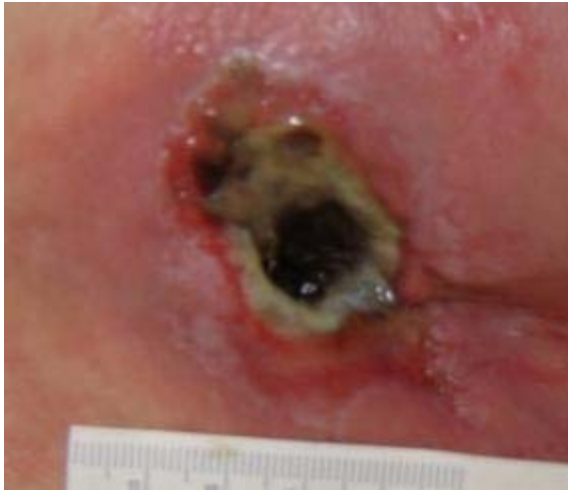

Wound now
measures
2.7 x 3.5 x 1cm

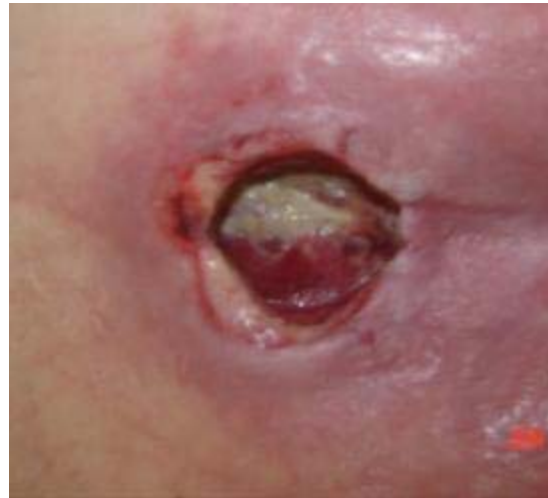- Patient continued to deteriorate in health and weight loss
- Dramatic decrease in odor noted by patient and family as the wound was autolytically debrided with MEDIHONEY®

Case 1 – Unstageable Pressure Ulcer

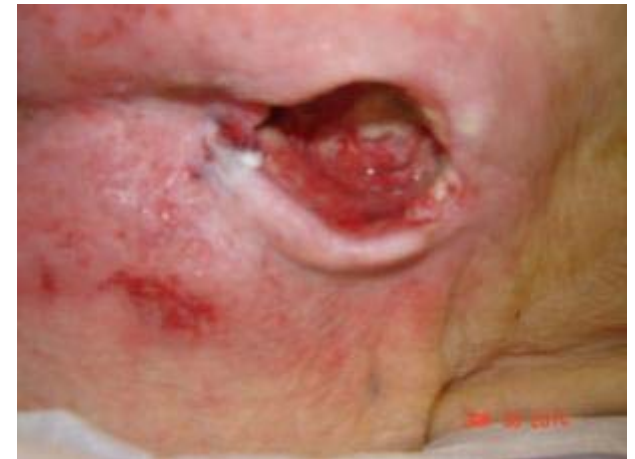Wound Progression



Day 1



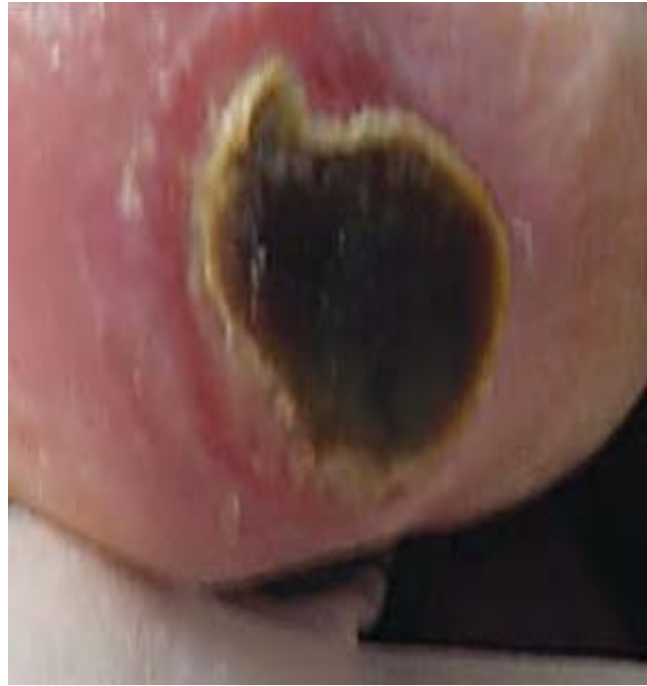Day 18



Day 30

Case 2 – Non-improving pressure ulcer on heel

Day 1

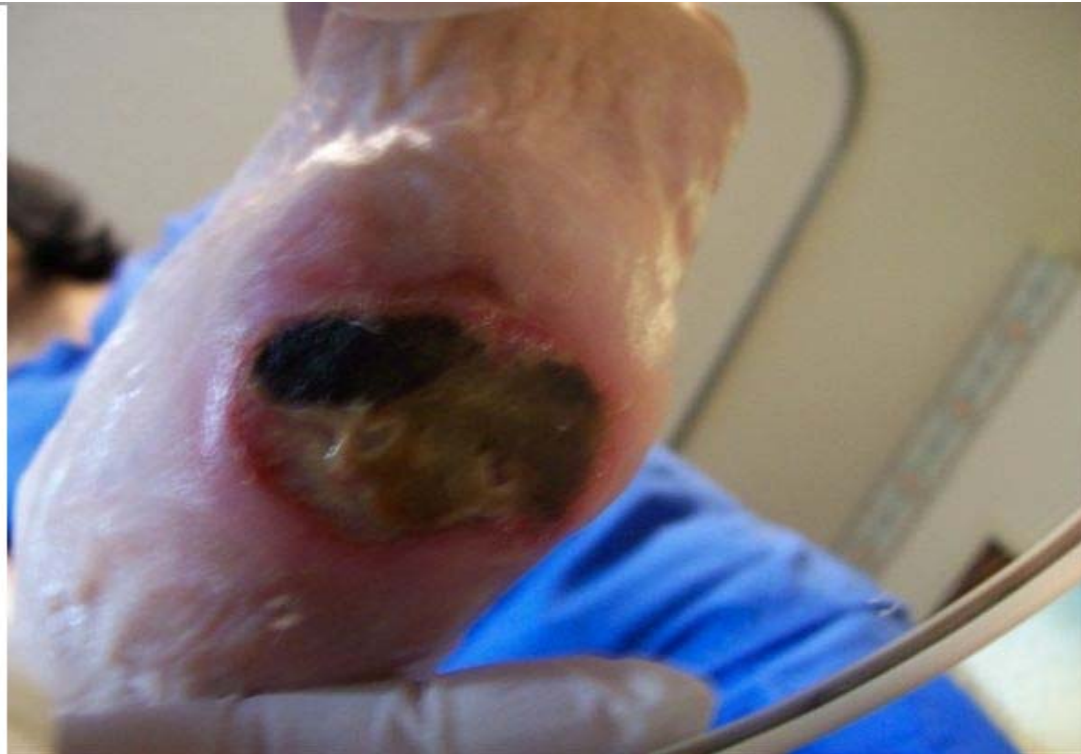

Wound Measurement
2 x 2.8 x 0

- 84 year old female with peripheral vascular disease
- Pressure ulcer on left heel. Treatment prescribed: collagenase daily
- Pressure redistribution surface for the bed and wheelchair
- Multivitamin with mineral daily, vitamin C , protein supplements

Case 2 – Non-improving pressure ulcer on heel

Day 90

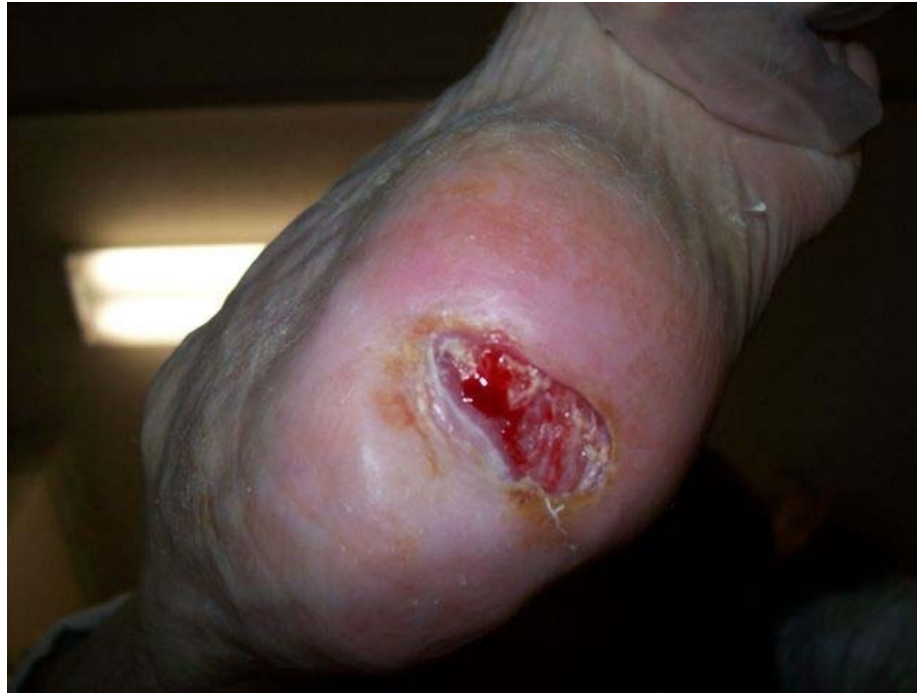

Wound
Measurement
3.4 x 2x0

- Eschar and slough still covering entire wound
- Changed treatment to MEDIHONEY® HCS sheet dressing, non-adherent
- Dressing frequency reduced from daily to 2x per week

Case 2 – Non-improving pressure ulcer on heel

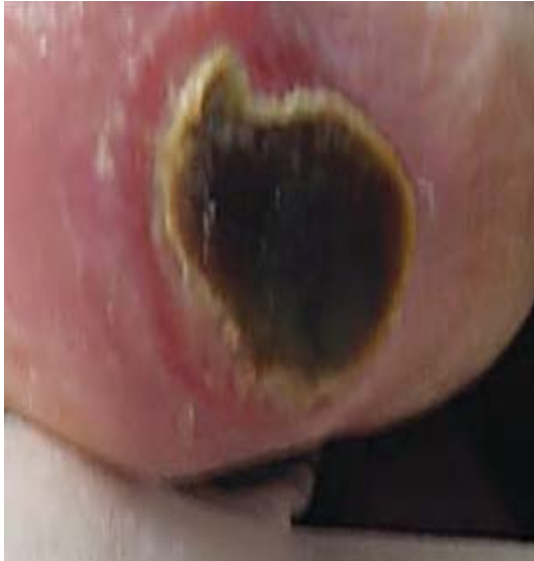Day 120



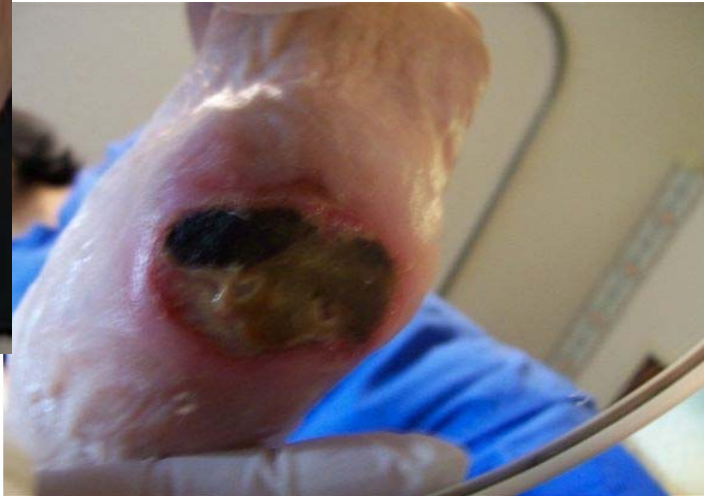Wound
Measurement
1 x 1.5 x 0.1

- Eschar, slough resolved
- Granulation tissue
- Epithelialization
- Maintained 2x per wk dressing changes
- Completely healed by day 60

Case 2 – Non-improving pressure ulcer on heel

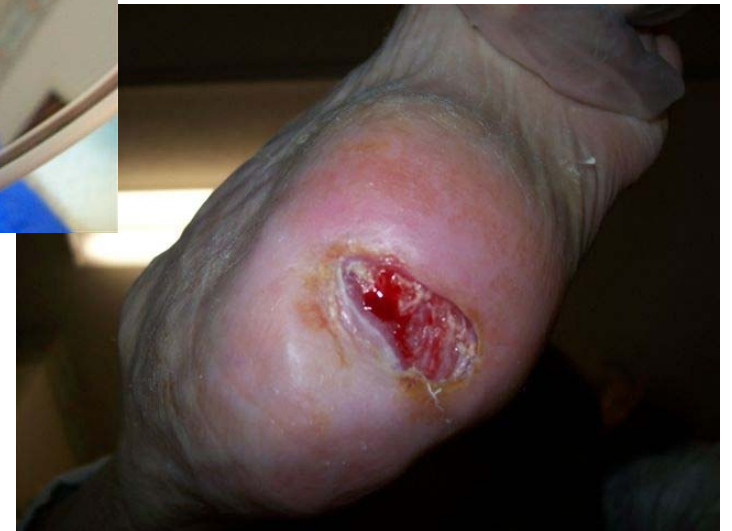

Day 1



Day 90

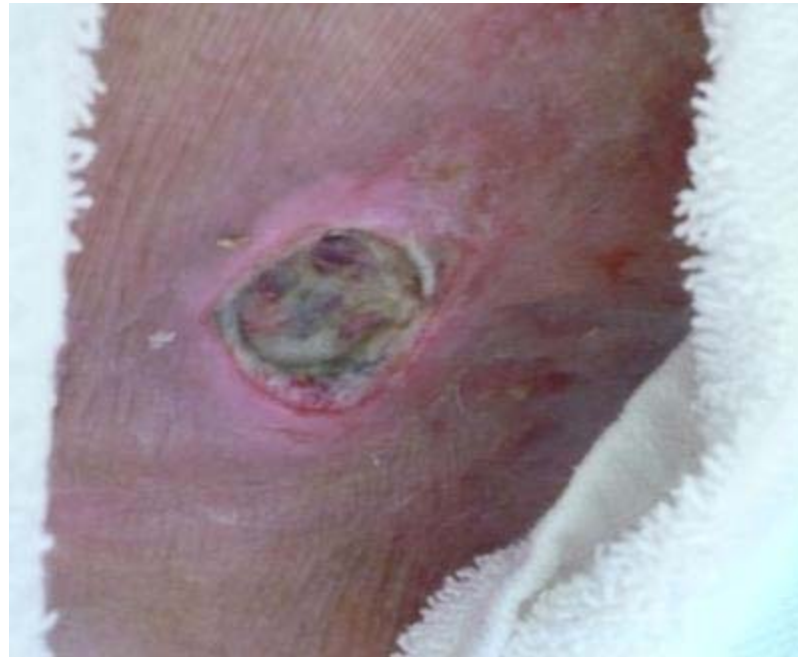* MEDIHONEY® initiated



Day 120

Case 3 – Unstable coccyx wound in end stage care

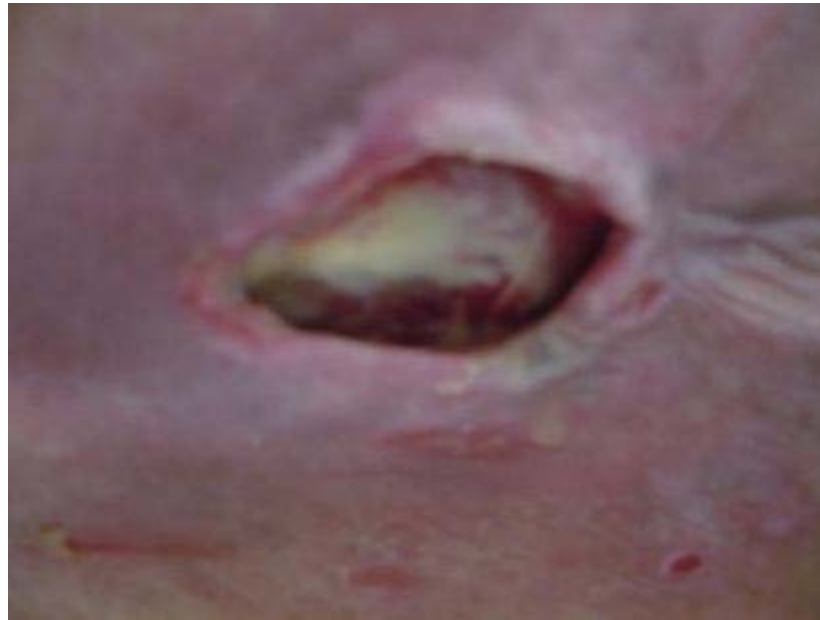Day 1



- 80 year old female with end stage dementia, COPD, and HTN
- Progressive weight loss - weighed 103 pounds
- Unstable coccyx wound
- Treatment: initiated MEDIHONEY® Gel and foam cover dressing
- Goal: Stabilize wound, remove slough to decrease odor

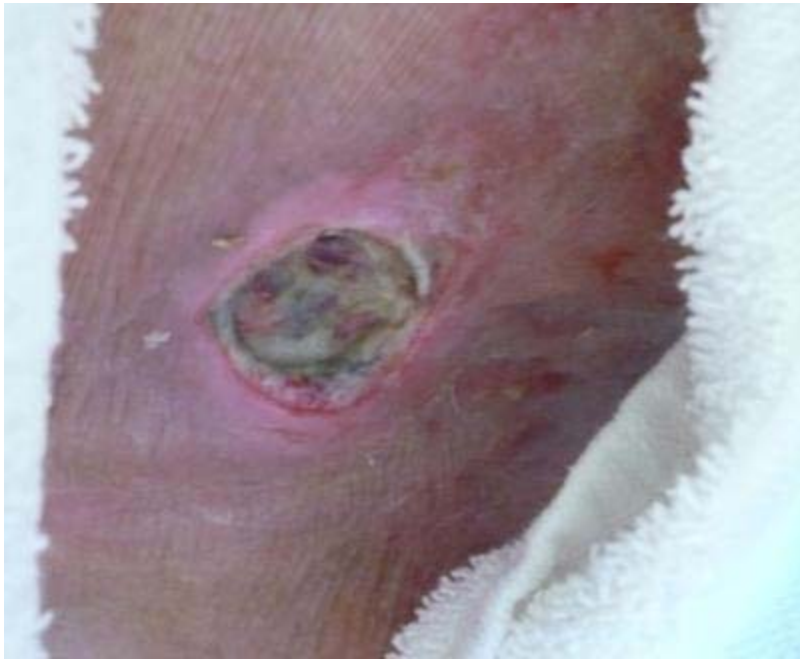Case 3 – Unstable coccyx wound in end stage care

Day 14

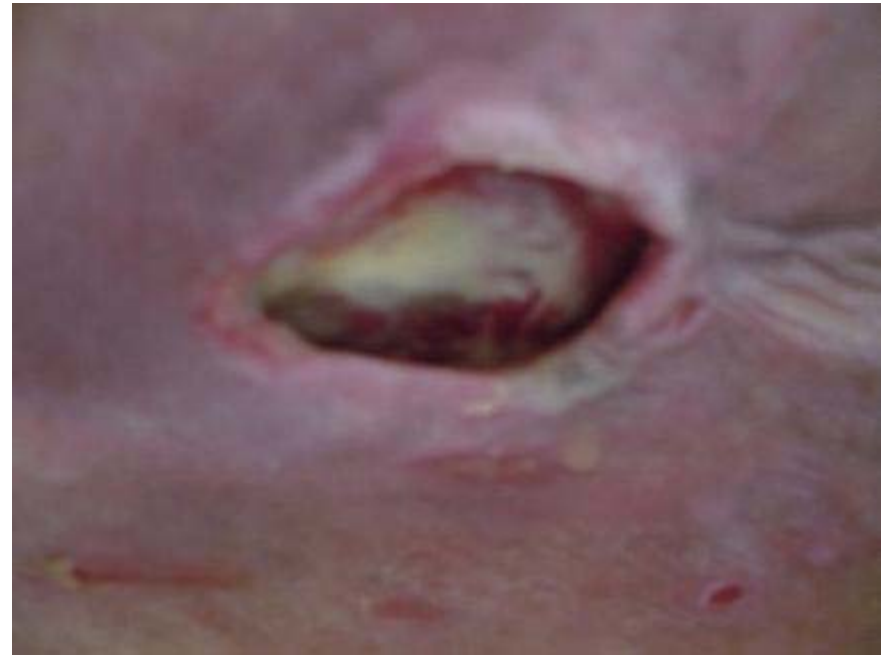

- Accomplished goals
 - Reduced slough
 - Reduction in odor observed by pt., family and staff
 - Pt. expired shortly afterwards

Case 3 – Unstable coccyx wound in end stage care



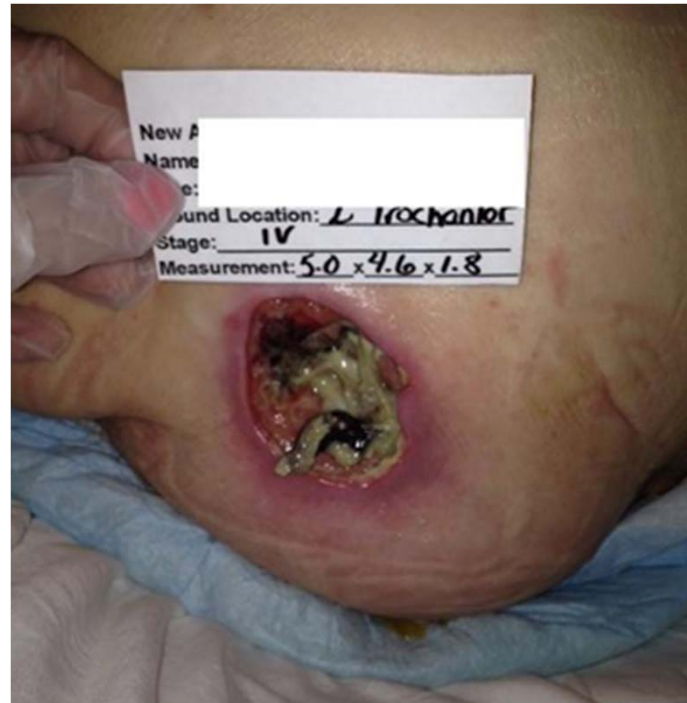Day 1



Day 14

Case 4 – Pressure Ulcer in Palliative Care Patient

Day 1

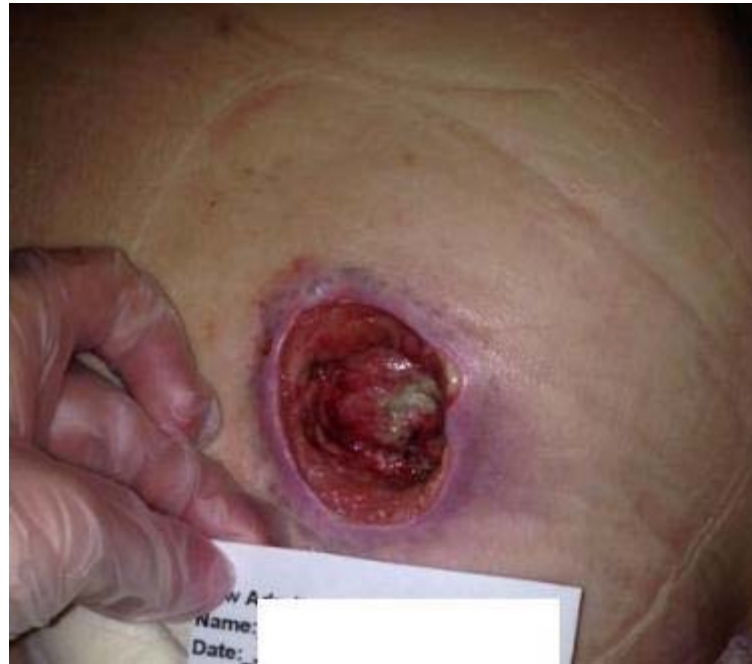

Wound
measurement
5.0 x 4.6 x 1.8

- 80yr LTC pt. End state Parkinson's disease, diabetes, dementia
- Pressure ulcer to left trochanter
- Conservative sharp debridement initiated

Case 4 – Pressure Ulcer in Palliative Care Patient

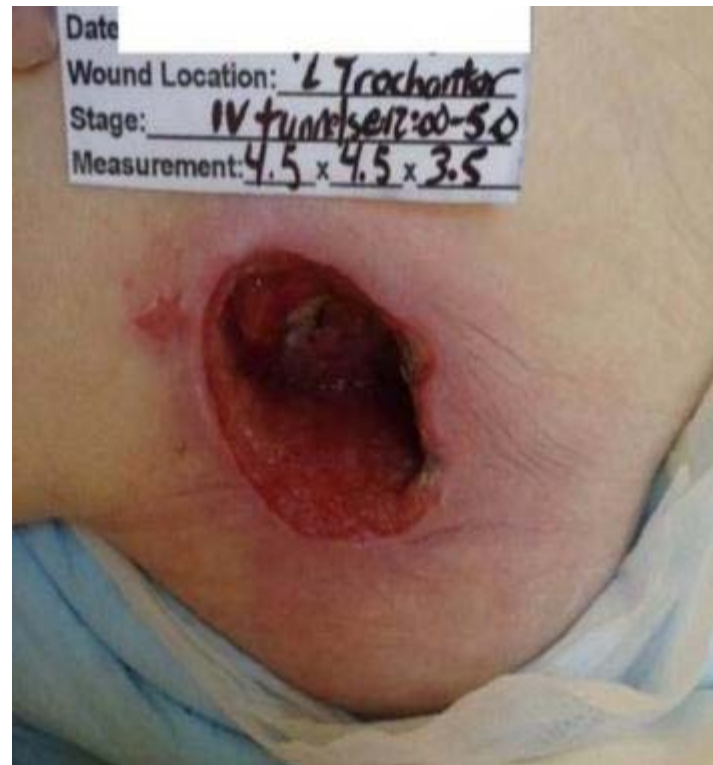Day 2



- Post conservative sharp debridement initiated
- Alternating pressure mattress
- Nutritional support – Multivitamin, Vit C, Protein supplement
- MEDIHONEY Calcium Alginate, 2 to 3x wk, secondary composite dressing

Case 4 – Pressure Ulcer in Palliative Care Patient

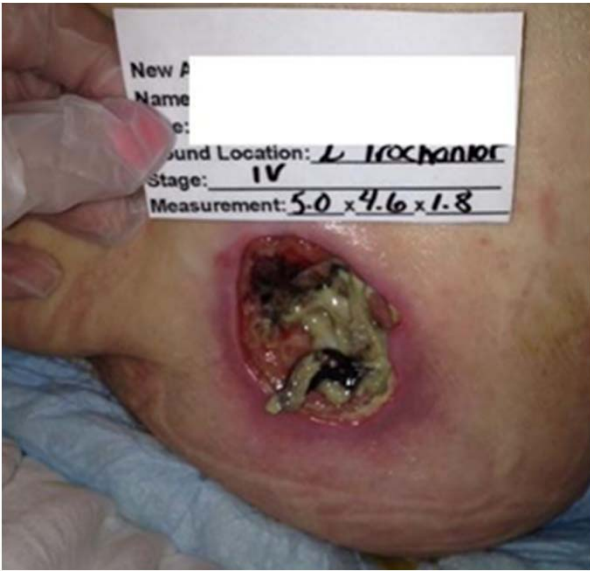Day 7



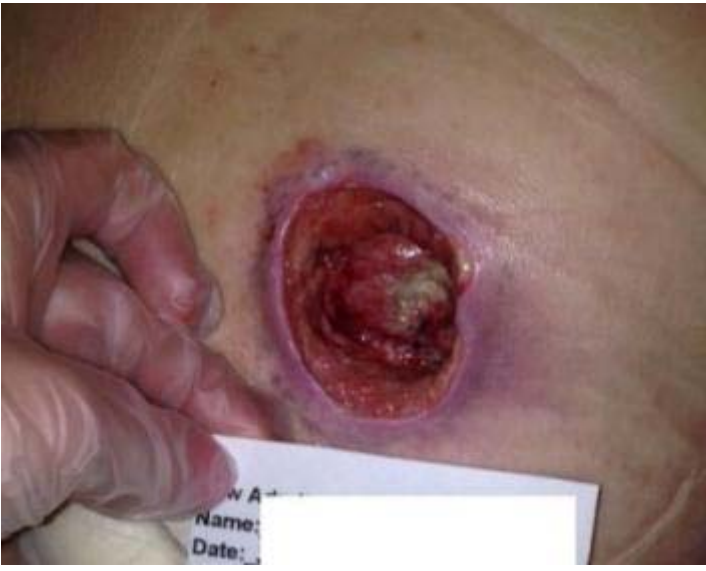Wound
measurement
4.5 x 4.5 x 3.5

- Granulation tissue presentation despite pt decline in health
- Pt observed wound was free from odor
- Continued with dressing changes 2x/ wk to aid in patient comfort
- Pt. unfortunately expired before additional images could be taken

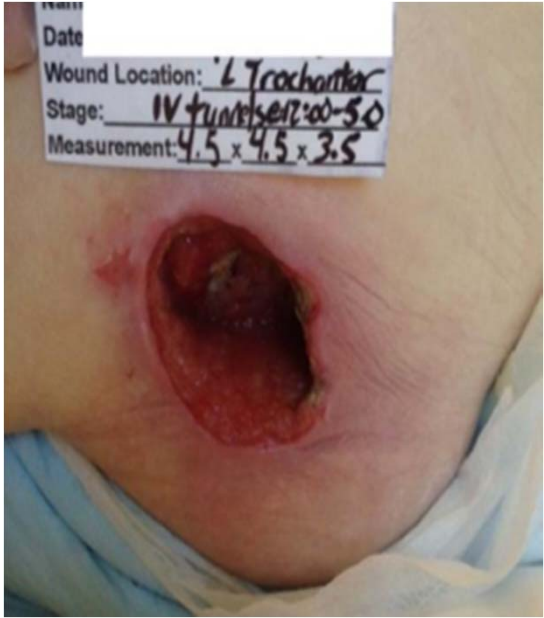Case 4 – Pressure Ulcer in Palliative Care Patient



Day 1

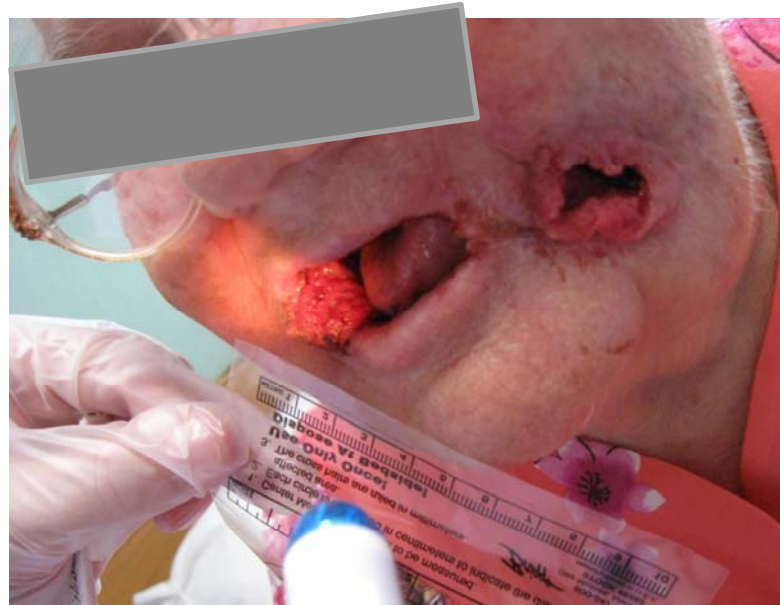

Day 2



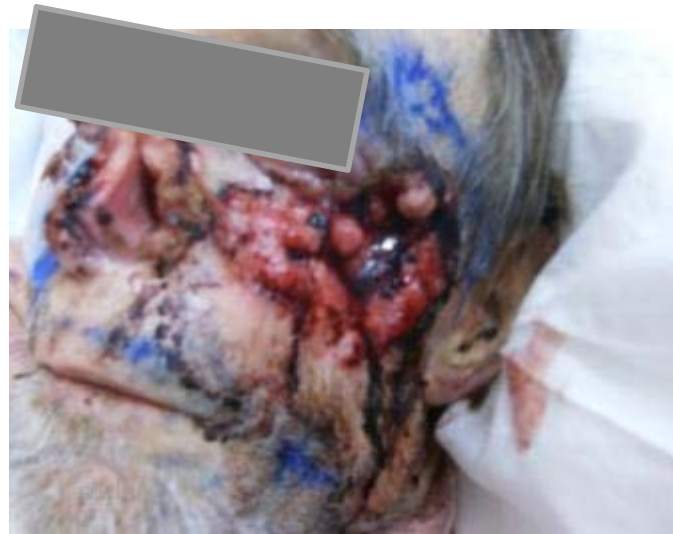Day 7

Case 5 – Facial Cancer Lesions at End Stage Care



- Cancer pt. developed facial lesions
- Pt reported pain and foul taste
- MEDIHONEY® Paste (100% Leptospermum honey) with light composite dressing
- Applied paste to inner cheeks 2x daily
- Pt observed reduced foul taste

Case 6 – Facial Cancer Lesions at End Stage Care



- Skin cancer biopsies and excision to remove cancer
- MEDIHONEY® Paste (100% Leptospermum honey) applied 2x daily and left uncovered to aid pt comfort
- Pt like pleasant smell of the MEDIHONEY and noted a reduction in odor
- Pt. expired a week later

Impact of MEDIHONEY® to Practice

- Help stabilize and prevent wounds from worsening
- Promote healing
- Promote dignity and quality of life
 - Removal of malodor tissue to aid in reducing odor
 - Less dressing changes – less discomfort
- Cost effective care

TIPS & Pointers

- Be prepared for an increase in exudate
 - Skin prep, absorptive cover
- Match product type to wound need:
 - PASTE = apply like any ointment, great for wounds of the mouth
 - GEL = apply like any ointment, more viscous and stays better at the wound site
 - Alginate dressing = More absorption, fit inside wound edges. Set expectations that the honey will move into the wound and the alginate is what is left
 - HCS Sheet dressing = for dry or lighter drainage, soft and comfortable.



Special Thanks

My Team

Anh Nguyen

Theresa Clackum

Sherry Shepard

Dawn Herndon



Thank you!



Presenter: Angel Sutton, RN, MSN/Ed, CWCN, CFCN, CCCN
Wound Care Nurse Consultant